

## Aero - Digestive Foreign Bodies in Tertiary Care Hospital of Southern Rajasthan: One Year Prospective Study

Lalit Kumar Raiger<sup>1</sup>, Ravindra Gehlot<sup>2</sup>, Anisha Banu<sup>3</sup>

<sup>1</sup>Senior Professor, <sup>2</sup>Assistant Professor, <sup>3</sup>Senior Resident, Department of Anaesthesiology, RNT Medical College, Udaipur, Rajasthan 313001, India.

### Abstract

*Background and Aim:* Foreign body lodgement in aero-digestive tract is a common surgical emergency presenting to the department which contributes to high morbidity and occasional mortality. Severity of symptoms depends upon the site, size, composition, and the period for which the foreign body has been present. Aim of our study was to analyze the event following foreign body aspiration in aero-digestive tract regarding-demographic characteristics of patients, history of event, type and site of foreign body, anaesthetic management and complications. *Method:* 65 cases of foreign body in aero-digestive tract (50 in food passage and 15 in airway), treated over one year period (prospectively) were reviewed. Foreign body retrieval was done by invasive procedures like laryngoscopy assisted / rigid endoscopy assisted under general anaesthesia. All the cases were done under controlled ventilation with muscle relaxant. In trachea-bronchial cases intermittent positive pressure ventilation via jet ventilation most commonly used technique. *Results:* The incidence of foreign body ingestion - in food passage 56% of patients were below 6 year of age, 30% between 3-6 years of age followed by 20% between 1-3 years. While in case of airway 53.33% were between the age group of 1-3 years. Most common site of lodgement of foreign body was cricopharynx (44%) in food passage and right main bronchus (53.33%) in airway. Most common foreign body found was coin (56%) in digestive tract, while vegetative foreign body (73.33%) in airway. In food passage most common symptom was dysphagia (82%) while in airway cough (66.66%) and difficulty in breathing (80%) were common findings. *Conclusion:* Foreign bodies in aero-digestive tract constitute a serious and potentially fatal situation usually occurring in pediatric population. Controlled ventilation with muscle relaxant is the preferred anaesthetic technique.

**Keywords:** Foreign body; Airway; Food passage; Endoscopy.

### How to cite this article:

Lalit Kumar Raiger, Ravindra Gehlot, Anisha Banu. Aero - Digestive Foreign Bodies in Tertiary Care Hospital of Southern Rajasthan: One Year Prospective Study. Indian J Anesth Analg. 2019;6(2):597-604.

### Introduction

Aero-digestive foreign bodies constitute an emergency problem which poses a great challenge in management, and failure to recognize or remove them promptly can lead to morbidity and

mortality [1]. Foreign body ingestion and inhalation are more common in children, especially in their first six years of life, with a peak incidence between 1 and 3 years of age, due to lack of molar teeth, tendency for oral exploration, to play during the time of ingestion and poor co-ordination during swallowing make them vulnerable to foreign body aspiration [2,3].

**Corresponding Author:** Anisha Banu, Senior Resident, Department of Anaesthesiology, RNT Medical College Udaipur, Rajasthan 313001, India.

**E-mail:** [dr.anishasheikh@gmail.com](mailto:dr.anishasheikh@gmail.com)

**Received on 20.12.2018, Accepted on 16.01.2019**

Foreign bodies in the aerodigestive tract present with a wide spectrum of clinical presentation. A large foreign body occluding the upper airway or esophagus may lead to severe symptoms and even sudden death whereas a small foreign body lodged in the aerodigestive tract may present with less severe symptoms [4,5]. The diagnosis and treatment of the problem require awareness and highest degree of suspicion of sign and symptoms of foreign body aspiration because it can mimic other conditions, particularly without a witnessed event, there can be delay in diagnosis and management which may lead to complications [6].

Anaesthetic management of removal of foreign body is still a challenge. Sharing of airway by both anaesthesiologist and endoscopist poses difficulty in ventilation, associated edema and inflammatory changes in tracheobronchial tree predisposes these patients to severe bronchospasm; so it requires a complete co-operation and good communication between anaesthesiologist and endoscopist [7].

Most of the studies which are available in literature have discussed various aspects of aero-digestive foreign bodies were conducted by ENT surgeons, which do not have much focus on anaesthetic considerations. Mostly data are available in the form of sporadic case reports, literature review or retrospective studies and there is scarcity of data which describes anaesthetic management of foreign body aspiration in aero-digestive tract. Hence we have done a one year prospective study of foreign body aspiration in aero-digestive tract with an aim to assess demographic profile, clinical presentation, anaesthetic management, peri-operative complications and outcome.

## Material and Method

After taking clearance from institutional ethical committee (IEC) a one year prospective observational (audit) study was carried out in the department of anaesthesiology (in the emergency operation theatre and E.N.T. operation theatre) at tertiary care hospital of southern Rajasthan (India). Study population include all consecutive patient presenting with foreign body aspiration at any point in the aero-digestive tract i.e. larynx, trachea, bronchi, hypo-pharynx, esophagus after informed risk and consent. A total of 65 patients were reported during one year duration.

*Statistical Analysis:* The data were assessed using complementary-descriptive statistical method. The categorical variables were expressed as percentage (%) values.

*Pre-Anaesthetic Evaluation And Preparation:* Detail evaluation including: demographics (Age, sex, socioeconomic status), Presenting complains (Sign, symptoms), history-(Presenting history, Past history, Surgical history, Any medication taken, Incident time, Sequence of events, Any sign of severe airway obstruction, Any management taken, NBM status), physical examination, investigations: available at that time (done previously and other ordered).

Patients with signs of severe airway obstruction were immediately taken for removal of foreign body without consideration of NBM status and oxygenation was done with poly mask till they are shifted to operation theatre. Depending on clinical condition following was given:

- Bronchodilator (Etophylline and theophylline)
- Steroids: hydrocortisone, dexamethasone

In every case following things were checked and kept ready-

- Secured I.V. line, O<sub>2</sub> supply, facility for mask ventilation & intubation, tracheostomy set, monitors, suction machine and various size of catheter, equipment for delivering O<sub>2</sub> and other gases like breathing circuits, venture device etc.

*Anaesthetic Management:* Foreign body retrieval was done by invasive procedures [like laryngoscopy assisted/rigid endoscopy assisted] depending upon the site of lodgment and nature of the foreign body and general anaesthesia was the preferred technique of choice. Patient vitals monitored were-pulse, SpO<sub>2</sub>, NIBP, ECG and precordial stethoscope was applied. All patients were premedicated with Inj. glycopyrrolate (0.005 mg /kg body weight), Inj. ondansetron (0.1 mg/kg body weight), Inj. midazolam (0.01 mg /kg body weight) depending upon clinical condition. Preoxygenation was done with 100% O<sub>2</sub> by bag and mask then induced with either inhalation/I.V. agents. After confirming assisted ventilation muscle relaxant was given and as soon as respiratory paralysis occurs patient was handed over to ENT surgeon for endoscopy (Apnoeic technique).

*Method of Ventilation:* Ventilation was maintained with either of these technique-

- I. In case of airway foreign body
  1. With Intermittent bag and mask ventilation/intermittent apnoea technique
  2. Jet ventilation/Venturi device

3. Ventilating bronchoscope
- II. In case of esophageal foreign body-
1. Intermittent bag and mask ventilation/ intermittent apnoea technique
  2. Positive pressure ventilation with Endotracheal intubation
- Anaesthesia was maintained with O<sub>2</sub>, inhalational or I.V. anaesthetic agent, muscle relaxant (depolarizing/non depolarizing) depending upon duration of procedure. After removal of endoscope, ventilation was maintained by bag and mask / if require intubation was done till spontaneous respiration return. Patients were further monitored till satisfactory recovery occurs and shifted to post operative ward. If required patients were further oxygenated through face mask or nasal prong. In Post operative period they were managed with bronchodilators, steroids, antibiotics, antihistaminics, humidified O<sub>2</sub> and chest physiotherapy.

### Observations

Out of total 65 patients, 50 patients had foreign body in food passage and in 15 patients in airway. 34 were males (52.3%) and females were 31 (47.6%) with a male to female ratio of 1.09:1. Their ages ranged from 8 month to 65 years. The incidence of foreign body ingestion in digestive tract is seen in a bimodal age group i.e. below 6 years of age (50%) with maximum in age group of 3-6 years (30%) then in group 1-3 years (20%). Second peak found in the age group >40 years (16%) cases. While the incidence of foreign body in airway shows that 53.33% of patients were between the age group of 1-3 years. The most common site of lodgement of foreign body in digestive tract was cricopharynx 22 cases (44%) followed by upper esophagus 18 cases (36%), then mid esophagus 8 cases (16%) and least at lower end of esophagus 2 cases (4%) [Figs 1 & 2]; While in the airway most common site of lodgement of foreign body was right main bronchus in 8 cases out of total 15, followed by left main bronchus 4 cases (26.66%), then in trachea 2 cases [Fig. 3] and one case showing foreign body in subglottic region.

Table 1 showed that coin was the most common foreign body in digestive tract 28 cases (56%) followed by meat bolus 9 cases (18%). While in the airway vegetative foreign body were more common found in 11 cases (73.33%); among vegetative

foreign body peanut was most common found in 7 cases (46.66%)(Table 2).

Ninety four (94)% of cases had witnessed foreign body in food passage while in case of airway only 33.3% had witnessed foreign body. Foreign body in food passage patients were having complaint of witnessed history, difficulty in feed, throat pain. while foreign body airway patients had H/O cough, difficulty in breathing, tachypnoea, fever and decrease air entry, wheeze/ crepts (Table 3).

The complication observed were laryngospasm, bronchospasm, post pharyngeal wall injury and upper incisor broken (2% each) in cases of food passage foreign body while in cases of airway foreign body bronchospasm (6.66%), voice change (6.66%), sore throat (33.33%) were seen. There was neither mortality nor tracheostomy was required in any case. In our study foreign body were retrieved in 48 (96%) cases from digestive tract and in all cases from airway. In 2 cases foreign body were not retrieved from esophagus as they were at lower end and after induction they goes further distally into the stomach. So they cannot be retrieved. These patients were observed in ward till the foreign body passed out through stool.

**Table 1:** Types of foreign body (Digestive tract)

Foreign body	No. of cases (n=50)	Percentage (%)
Battery cell	7	14
Coin	28	56
Meat bolus	9	18
Vegetative	2	4
Fish bone	1	2
Plastic object	1	2
Safety pin	1	2
Ear tops(pointed end)	1	2

**Table 2:** Types of foreign body (Airway)

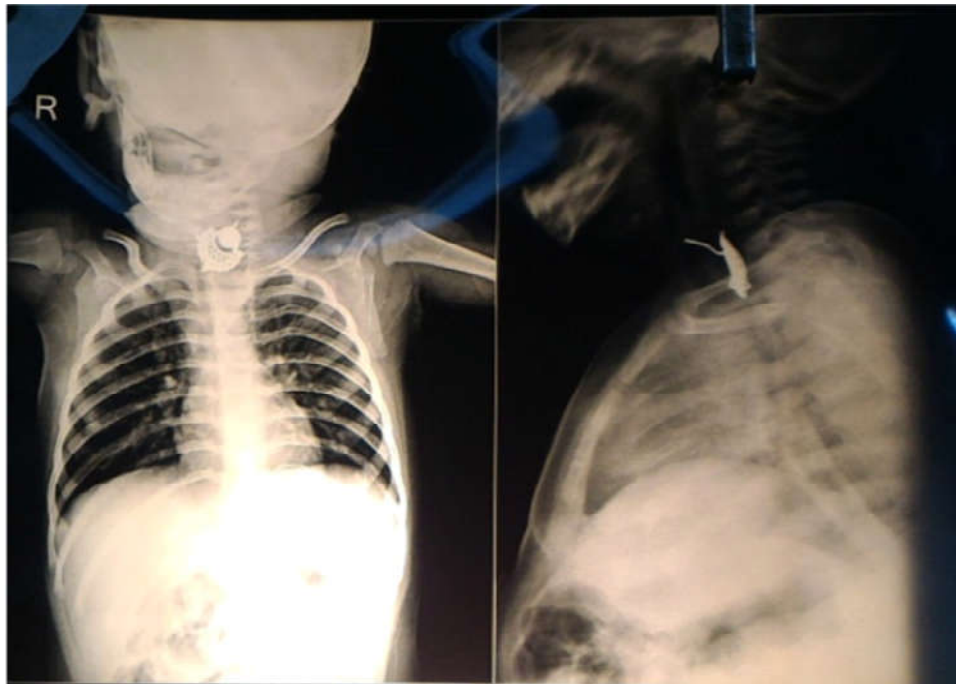
Foreign body	No. of cases (n=15)	Percentage (%)
Metallic	2	13.33
Safety pin	1	6.66
Wire	1	6.66
Vegetative	11	73.33
Ground nut	1	6.66
Peanut	7	46.66
Rayma seed	1	6.66
Setaphalseed (custard apple seed)	1	6.66
Supari (Betel nut)	1	6.66
Plastic object	2	13.33

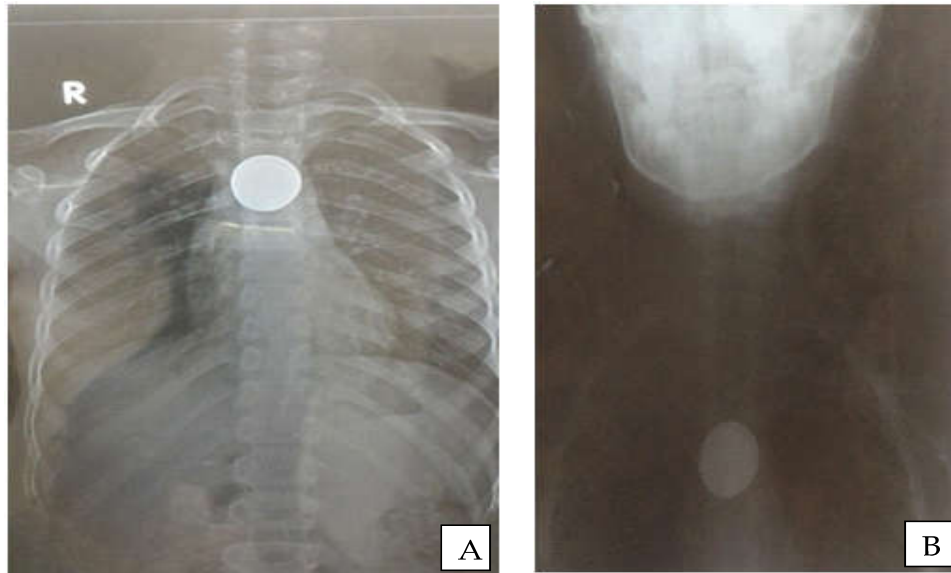
**Table 3:** Signs and Symptoms in patients with airway foreign bodies

	No. of cases (n=15)	Percentage (%)
<i>Symptoms</i>		
Cough	10	66.66
Difficulty in breathing	12	80
Fever	3	20
Respiratory distress	1	6.66
Voice change	1	6.66
Blood stained sputum	1	6.66
Stridor	1	6.66
<i>Signs</i>		
Tachypnoea	8	53.33
Decrease air entry on both side	3	20
Decrease air entry on right side	5	33.33
Decrease air entry on left side	5	33.33
Bilateral wheeze	5	33.33
No sign	2	13.33
Intercostal retraction	1	6.66

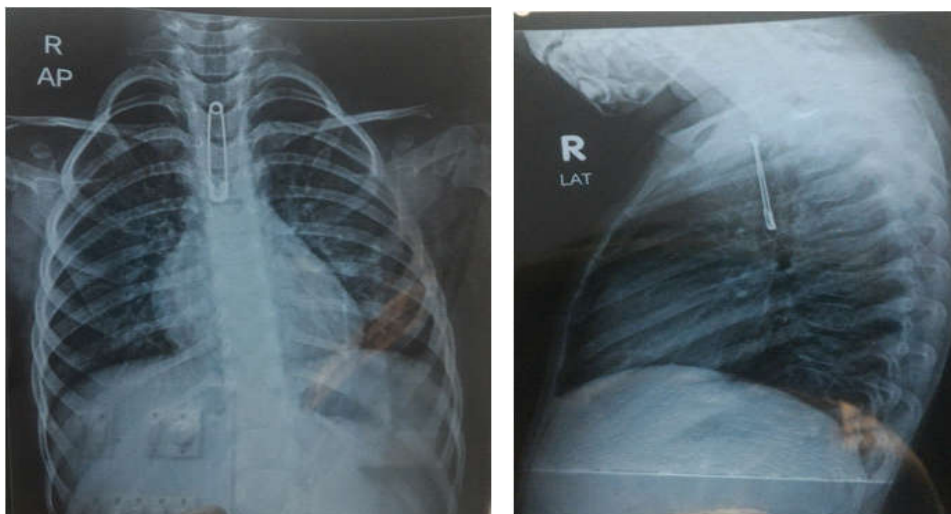
**Table 4:** Radiological features of foreign bodies

X-ray- chest/neck	Airway FB n=15 (%)	Food passage FB n=50(%)
Obstructive emphysema	7 (46.66)	-
Collapse	2 (13.33)	-
Consolidation	1 (6.66)	-
Normal X ray	3 (33.33)	14
Metallic Foreign body seen with normal lung fields	2 (13.33)	36

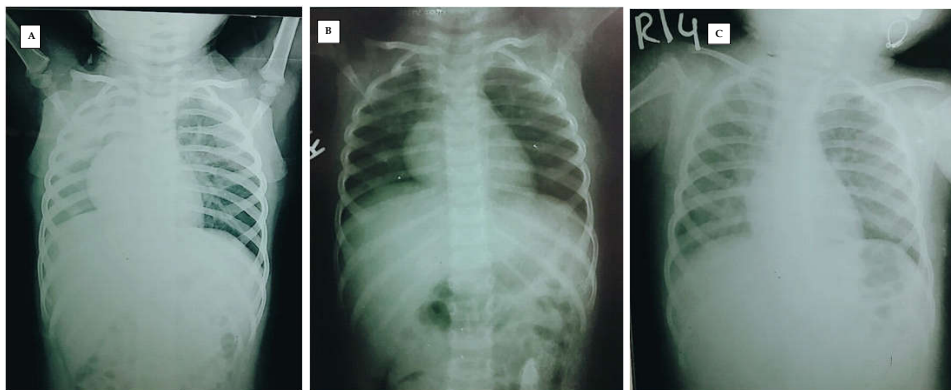
**Fig. 1:** Chest X-Ray (PA and lateral view) of 8 month old patient showing metallic foreign body (pointed edge impinging on trachea) at upper end of esophagus.



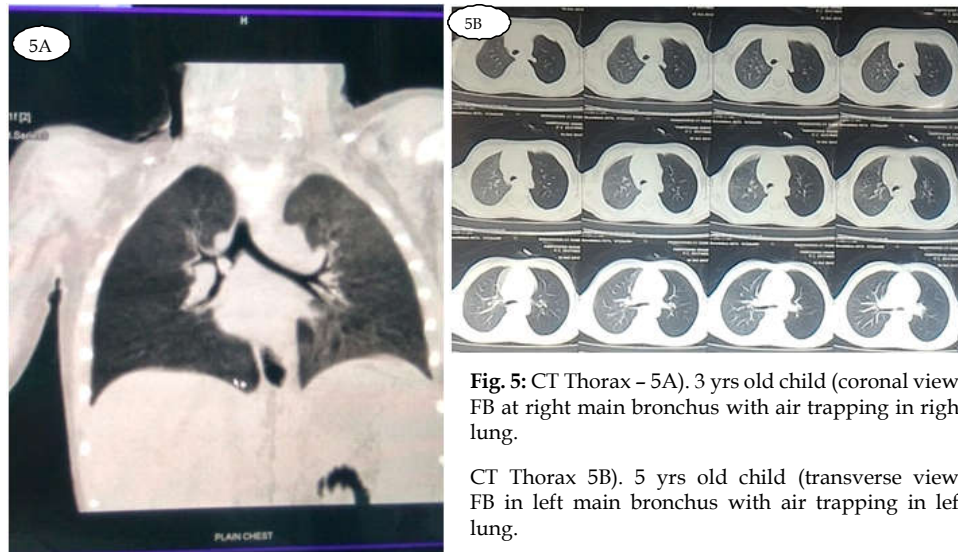
**Fig. 2:** A. CXR (PA view) of a 8 yrs old child -showing metallic foreign body (Double coins); B. foreign body (coin) at mid esophagus level



**Fig. 3:** CXR (AP and Lateral view) of a 3 yrs old female showing metallic foreign body (safety pin) in trachea.



**Fig. 4:** CXR (AP view) of 18 month old child after aspiration of a vegetative foreign body in right main bronchus - showing A. Collapse of right lung with mediastinal shift and tracheal deviation toward right side B. post bronchoscopy CXR (AP View) 24 hrs after removal of FB C. 48 hrs after removal of foreign body.



**Fig. 5:** CT Thorax - 5A). 3 yrs old child (coronal view) FB at right main bronchus with air trapping in right lung.

CT Thorax 5B). 5 yrs old child (transverse view) FB in left main bronchus with air trapping in left lung.

## Discussion

Foreign bodies lodgement in the aerodigestive tract are a common surgical emergency presenting to Emergency department in many centers with the highest incidence among children and contribute significantly to high morbidity and occasionally mortality. Children below the age of 6 years are more vulnerable because of curiosity and their new found abilities of locomotion; as they have natural propensity of gaining knowledge, putting things into mouth, inability to masticate well (molar appears at 4 yrs of age) and inadequate control of deglutition along with habit of crying, shouting, laughing and playing during meals, constitutes some of predisposing factors [8-12]. Cricopharynx is most common site of foreign body lodgement in digestive tract as the cricopharynx is the first anatomical constriction [13]. While in the airway foreign body lodgements are more common in right bronchus than left, as right bronchus is more vertical and wider than left ones [14]. Similar foreign body's lodgment patterns were also reported by others [15-17].

As coin is the most common foreign body in food passage among children while meat bolus among adult; and in the airway vegetative foreign body (peanuts) were more common. The reason for this may be due to free access to objects, children have to coins in our environment, which are usually given as gifts and the habit of oral exploration by the children. In children, nuts cannot be properly masticated due to the absence of molar teeth and nuts fragmented by incisors are much more likely to be aspirated. Hence, it is advisable not to offer

nuts and seeds to small children, who are liable to aspirate them into the respiratory passage [18].

The dysphagia as most common symptom and odynophagia/dysphagia & drooling of saliva was found to be a more reliable indicator of a retained foreign body in pharyngoesophagus passage. This results of our study are concise with other studies [19-21] which also state that cough, dyspnea and choking were the common presentation for airway foreign body [Table 3]. Among the signs, tachypnea, diminished breath sounds, and ronchi/crepitations were more common. Clear presenting symptoms may be lacking in some patients, which may be due to the fact that approach was significantly delayed in most of our cases due to poor referral/home remedy or waiting to pass down. The finding can be explained clinically by rapid fatigue of the cough reflex which can occur within 15 min secondary to desensitization of the cough receptors or due to fatigue of breathing against resistance. So the acute episode can be missed within a short span of time. Very high index of suspicion is required especially in case of children in which acute episode may occur without parent's knowledge and the delayed symptoms indicated other pathology such as asthma, pneumonia, bronchitis [17].

Obstructive emphysema was the most common radiological finding (Table 4). However normal X-ray does not negate the diagnosis of a foreign body in the respiratory passage. Diagnostic imaging plays a variable role in identifying tracheobronchial foreign bodies. Most of the foreign bodies are not radiopaque and small foreign bodies may cause symptoms but no radiographic signs. Plain films may be inadequate to document a non radiopaque foreign body unless

they are obtained in the expiratory phase. On expiration, air trapping, obstructive emphysema and mediastinal shift may be demonstrated [Fig. 4 & 5].

In present study we used controlled ventilation technique in every case as the use of muscle relaxant keeps the patient totally quiet during the procedure; the bronchial caliber does not vary and permits easy introduction of endoscope. Patrick t. Farrell [22] suggested that positive pressure ventilation with muscle relaxation is preferred as it improve oxygenation, facilitate smooth removal of foreign body, reduce untoward anaesthetic effects on cardiac output, and also known to reduce risk of atelectasis and overcome the increased airway resistance; and the disadvantage is that there are more chances to dislodge the foreign body which may move more distally and more chances of barotraumas. While in spontaneous ventilation there is lower risk compared to with controlled ventilation that the foreign body may move more distally, which would increase difficulty of removal and possibly lead to ball-valve obstruction. It also allows continued ventilation during removal of foreign body and rapid assessment of the adequacy of the airway after removal. Disadvantage is that depth of anaesthesia required to permit the insertion of instruments into the airway, decreases both cardiac output and ventilation and there is increased resistance to ventilation during use of endoscope worsen the hypoventilation [22]. According to Liu Y [23] controlled ventilation also decreases the risk of laryngospasm; this help in smooth retrieval of foreign body and early post operative recovery.

The most commonly reported complications include failure in removing the FB, laryngeal edema, pneumothorax, pneumomediastinum, subcutaneous emphysema, tracheotomy or assisted ventilation necessity for laryngeal obstruction or respiratory distress, hypoxic brain events, bradycardia, cardiopulmonary arrest and even death [24]. but in our study we had laryngospasm, bronchospasm, sore throat, posterior pharyngeal wall injury. Neither any case of hypoxic brain injury, cardiopulmonary arrest nor any tracheostomy was seen. The idea of dealing with a very young child with a history of inhalation of foreign body can be a daunting task not only because of the demands that removal of a foreign body makes on their skills, but also on the account of the unpredictability in the degree of difficulty of the procedure.

## Conclusion

From present study we conclude that foreign

bodies in aero-digestive tract constitute a potentially fatal situation usually occurring in pediatric population with peak incidence below 6 years of age. Controlled ventilation with muscle relaxation should be preferred for endoscopy. Since aero-digestive foreign bodies are preventable surgical condition, parents should be educated to keep a close eye on their children and keep objects (foreign bodies) away from children's reach.

## References

1. Kamath, P., Bhojwani, K. M., Prasannaraj, T., Abhijith, K. Foreign bodies in the Aero digestive tract – a clinical study of cases in the coastal belt of South India. *American Journal of Otolaryngology-Head and Neck Medicine and Surgery*. 2006;27; 373-77.
2. Jimenez F.I., Segura G.C., Munoz A.V., Mata P.D. Foreign Body aspiration in childhood - a report of 210 cases. *An Esp Pediatr*. 2000 Oct;53(4):335-8.
3. Higo R, Matsumoto Y, Ichimura K, Kaga K. Foreign Bodies in the aerodigestive tract in pediatric patients. *AurisNasus Larynx*. 2003 Dec;30(4):397-401.
4. Bist SS, Varshney S., Kumar R., Saxena R.K. Neglected bronchial Foreign body in an adult: a case report. *JK Science*. 2006;8(4):222-24.
5. Stool D, Rider G, Welling JR: Human factors project: development of computer models of anatomy as an aid to risk management. *Int J Pediatr Otorhinolaryngol*. 1998;43(3):217-27.
6. Samad L, Ali M, Ramzi H. Tracheobronchial foreign body aspiration in children: Reaching a diagnosis. *J Pak Med Assoc*. 1998;48(11):332-34.
7. Sehgal A, Singh V, Chandra J, Mathur NN. Foreign body aspiration. *Indian Pediatrics*. 2002; 39:1006-1010.
8. Fidkowski CW, Zheng H, Firth PG. The anesthetic considerations of tracheobronchial foreign bodies in children: a literature review of 12,979 cases. *Anesth Analg*. 2010;111:1016-25.
9. Shivkumar A.M., Palakshappa K.R., Naik A.S., Prashanth K.B., Yogesh B.S. Preferred anaesthetic technique for tracheobronchial foreign body - A otolaryngologist's perspective. *Indian J. Anaesth*. 2004;48(2):145-47.
10. Kalyanappagol V.T., Kulkarni N.H., Bidri L.H. Management of tracheobronchial foreign body aspiration in pediatric patient. *Indian J. Anaesth*. 2007;51(1):20-23.
11. Kulkarni J.V., Bhagat H.P.: A Retrospective study of anaesthetic management of foreign bodies in airway. *Indian J. Anaesth*. 2007;51(6):501-04.
12. Zur K.B., Litman R.S. Pediatric airway foreign body retrieval - surgical and anaesthetic perspectives: *Pediatric Anaesthesia*. 2009;19(1):109-17.

13. Gilyoma JM. Endoscopic procedures for removal of foreign bodies of the aerodigestive tract. The Bugando Medical Centre Experience. *Ear, Nose and Thorat Disorders*. 2011;11:2.
  14. Schmidt H, Manegold BC: Foreign body aspiration in children. *SurgEndosc*. 2000;14(7):644-8.
  15. Hariga I, Khamassi K, Zribi S. Management of foreign bodies in aerodigestive tract. *Indian J Otolaryngol Head Neck Surg*. 2014;66:220-24.
  16. Dereci S., Koca T., Serdaroglu F., AkcamM.: Foreign body ingestion in children: Turk pediatric Ars. 2015; 50(4):234-40.
  17. Blazer S, Naveh Y, Friedman A: Foreign bodies in the airway: A review of 200 cases. *Am J Dis Child*. 1980;134:68-71.
  18. Steen K. H.and Zimmerman M.D. Tracheobronchial aspriation foreign bodies in children - A study of 94 cases. *The Laryngoscope*. 1990;100(5):525-30.
  19. Kaur K, Sonkhya N, Bapna AS: Foreign body in tracheobronchial tree—A prospective study of 50 cases. *Indian J Otolaryngol*. 2002;54(1):29–30.
  20. Jaswal A, Jana U, Maiti P. Trachea-bronchial foreign bodies: a retrospective study and review of literature. *Indian J Otolaryngol Head Neck Surg*. 2014;66:156-160.
  21. Annigeri RV, Patil RS. A retrospective analysis on anesthetic management during rigid bronchoscopy in children with foreign body aspiration: Propofol and sevoflurane with controlled ventilation. *Anesth Essays Res*. 2017;11:871-4.
  22. Farrell PT. Rigid bronchoscopy for foreign body removal: Anaesthesia and ventilation. *Paediatr Anaesth*. 2004;14:84-9.
  23. Liu Y, Chen L, Li S. Controlled ventilation or spontaneous respiration in anesthesia for tracheobronchial foreign body removal: A meta-analysis. *Paediatr Anaesth*. 2014;24:1023-30.
  24. Jones NS, Lannigan FJ, Salama NY. Foreign bodies in the throat: a prospective study of 388 cases. *The Journal of Laryngology & Otology*. 1991;105(2):104-8.
-